

Nine Years' Follow-up of Bilateral Extremely Low Vaulting of Implantable Collamer Lens: Case Report

Nicole Mechleb, MD; Damien Gatinel, MD; Alain Saad, MD

ABSTRACT

PURPOSE: To present a patient with bilateral implantable Collamer lens (ICL) implantation with extremely low vault who was followed up over 9 years and in whom no cataract was detected.

METHODS: A 56-year-old woman underwent uneventful bilateral ICL implantation and her postoperative ICL vaulting was 10 and 8 μ m in the right and left eye, respectively. After consultation with the patient, it was decided to withhold surgical intervention and follow up closely.

RESULTS: Nine years postoperatively, the patient had normal

ophthalmological examination results: uncorrected distance and near visual acuity of 20/20, normal intraocular pressure and open angle, stable ICL with low vaulting of 8 to 12 μ m, clear lens with stable Objective Scatter Index scores, and normal posterior segment.

CONCLUSIONS: This case report shows that even though low ICL vault is a risk factor for cataract development, withholding surgical intervention should be considered depending on the patient's age, characteristics, and compliance with close follow-up.

[*Journal of Refractive Surgery Case Reports*. 2023;3(1):e5-e9.]

The posterior chamber phakic intraocular lens (pIOL) has revolutionized treatment of patients with myopia who are not candidates for laser refractive surgery. Currently, the only posterior chamber pIOL approved by the U.S. Food and Drug Administration is the Visian Implantable Collamer Lens (ICL; STAAR Surgical).¹ The ICL's advantages include faster visual recovery, high efficacy and visual stability, and reversibility.² However, the ICL is associated with complications that warrant explantation or exchange in less than 4% of patients.³ Improper sizing with consequent extreme vaulting is the main cause of explantation, accounting for 68% to 78%. Secondary cataract is the second most common reason for explantation (12% to 13%).⁴ We present herein a case of bilateral ICL with extremely low vault who was followed up over a period of 9 years and in whom no cataract was detected.

This case report shows that even though low ICL vault is a risk factor for cataract development, withholding surgical intervention should be considered depending on the patient's age, characteristics, and compliance with close follow-up.

CASE REPORT

A 56-year-old healthy White woman presented to our refractive surgery department in September 2013. Her corrected distance visual acuity was 20/20 with -8.75 (-3.50 \times 20°) and -7.75 (-2.00 \times 160°) in the right and left eyes, respectively. Ophthalmological examination of the anterior and posterior segments was within normal limits; notably there was no significant cataract and iridocorneal angle was open 360° (Shaffer grade 4). The Optical Quality Analysis System (OQAS) (Visiometrics SL) showed an Objective Scatter Index

From the Anterior Segment and Refractive Surgery Department, Rothschild Foundation Hospital, Paris, France (NM, DG, AS); and Center of Expertise and Research in Optics for Clinicians, Paris, France (DG).

© 2023 Mechleb, Gatinel, & Saad; licensee SLACK Incorporated. This is an Open Access article distributed under the terms of the Creative Commons Attribution 4.0 International (<https://creativecommons.org/licenses/by/4.0>). This license allows users to copy and distribute, to remix, transform, and build upon the article, for any purpose, even commercially, provided the author is attributed and is not represented as endorsing the use made of the work.

Submitted: October 29, 2022; Accepted: February 3, 2023

Disclosure: The authors have no financial or proprietary interest in the materials presented herein.

Correspondence: Alain Saad, MD, Anterior Segment and Refractive Surgery Department, Rothschild Foundation Hospital, 25 rue Manin, 75019 Paris, France. Email: dralainsaad@gmail.com

doi:10.3928/jrscr-20230203-01

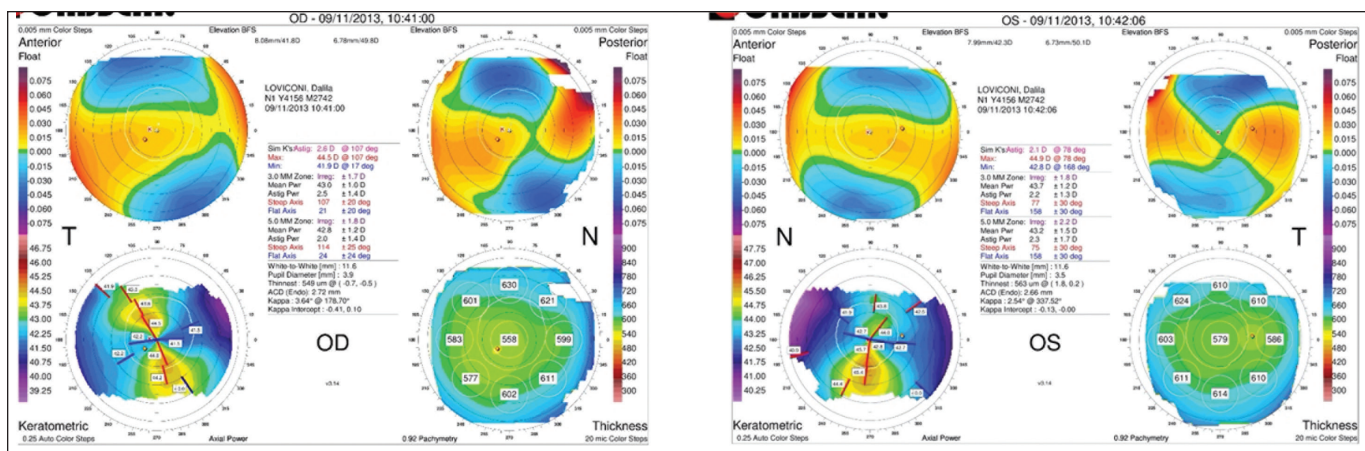


Figure 1. Preoperative corneal topography of the right (OD) and left (OS) eyes using the Orbscan corneal topography system (Bausch & Lomb) precluding laser in situ keratomileusis for the correction of the high ametropia of the patient: anterior curvature showing asymmetric bowtie/inferior steep with skewed radial axis in the left eye and loss of corneal enantiomorphism.

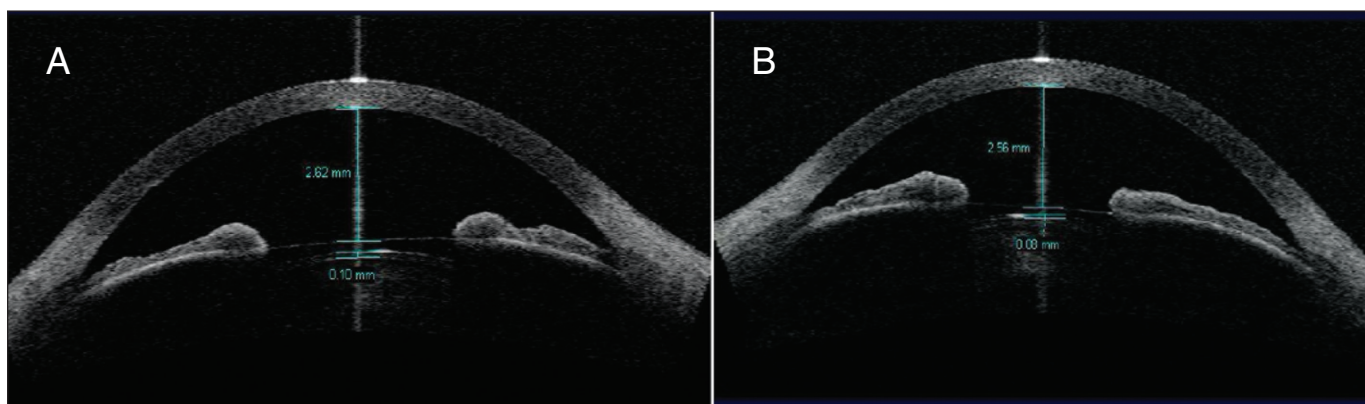


Figure 2. Postoperative anterior segment optical coherence tomography of the (A) right and (B) left eyes showing implantable Collamer lens vaulting of 10 and 8 μm , respectively. No anterior subcapsular opacification is noted.

(OSI) score of 1.5 bilaterally. Our patient was not a good candidate for laser in situ keratomileusis because corneal topography of her left eye revealed moderate ectasia risk (**Figure 1**). We discussed therapeutic alternatives with the patient, in particular the benefits and risks of ICL implantation and the risk of postoperative cataract and residual astigmatism, and she opted for bilateral ICL implantation.

The patient underwent uneventful bilateral ICL implantation. Postoperative ICL vaulting was 10 and 8 μm in the right and left eyes, respectively (**Figure 2**). On re-evaluation, unexpected low vaulting was not related to any error in sizing calculations. Because our patient was already at higher risk of developing cataract even without ICL implantation due to her age, and because no direct contact between the ICL and anterior capsule was noted, we decided to observe and withhold ICL exchange or explantation if her lens remained clear. At 1 month postoperatively, the patient had a refraction of $-0.25 -1.75 \times 45^\circ$ and $+0.50 -0.25 \times 140^\circ$ in the right and left eyes, respec-

tively, and persistent low ICL vault with otherwise normal examination and satisfactory visual acuity. Bilateral uncomplicated low ICL vaulting remained stable over time. Further laser fine tuning of the right non-dominant eye to achieve monovision was done.

Table 1 summarizes the refraction, visual acuity, air-puff tonometry, and OQAS score over the follow-up period. At 1 month after photorefractive keratectomy, bin-ocular uncorrected visual acuity was 20/20 for distance and near vision, and her right and left eye refraction were $-1.75 (-0.75 \times 140^\circ)$ and $+0.25 (-0.50 \times 155^\circ)$, respectively. We followed up the patient postoperatively at 1, 3, 6, 12, and 18 months, and then yearly for 9 years. No clinically significant cataract developed and OSI scores fluctuated between 1.5 and 2.6 over the follow-up period (**Figure 3**). At the last follow-up visit in June 2022, the patient was 65 years old and her ophthalmological examination was within normal limits: uncorrected distance and near visual acuity of 20/20, normal intraocular pressure and open

TABLE 1
Vision, Refraction, ICL Details, Biometry Parameters, ICL Vaulting, Endothelial Cell Counts, and OQAS Score at Each Visit

Parameter	Right Eye	Left Eye
Pre-ICL		
UDVA	CF 2 m	CF 2 m
CDVA	20/20	20/20
CNVA	P2	P2
Refraction	-8.75 (-3.50 × 20°)	-7.75 (-2.00 × 160°)
ACD (mm), Orbscan II	2.72	2.66
WTW diameter (mm)	11.6	11.6
AL (mm), IOLMaster	27.27	26.43
IOP (mm Hg)	15	16
OSI score	2.6	1.5
ICL details		
Type	Visian ICL; STAAR Surgical	Visian ICL; STAAR Surgical
Optic diameter (mm)	5.5	5.5
Overall diameter (mm)	12.6	12.6
Power (D)	-11.00/+3.50	-10.50/+2.00
Post ICL (4 weeks)		
UDVA	20/20	20/20
CDVA	20/20	20/20
CNVA	P2	P2
Refraction	-0.25 (-1.75 × 5°)	+0.50 (-0.25 × 140°)
ACD (mm), Orbscan II	2.95	2.92
ICL vaulting (μm)	10	8
IOP (mm Hg)	17	18
OSI score	2.6	1.1
Postop right eye PRK (1 month)		
CDVA	20/20	
Refraction	-2.25 (-1.25 × 150°)	
ICL vaulting (μm)	10	
OSI score	2.6	
Last follow-up (9 years after ICL)		
Uncorrected binocular visual acuity	20/20 P2	
CDVA	20/20	20/20
Refraction	-1.75 (-0.75 × 140°)	+0.25 (-0.50 × 155°)
ACD (mm), Orbscan II	2.55	2.43
ICL vaulting (μm)	9	8
IOP (mm Hg)	17	19
OSI score	2.3	2.3

ACD = anterior chamber depth; AL = axial length; CDVA = corrected distance visual acuity; CF = counting fingers; CNVA = corrected near visual acuity; D = diopters; ECD = endothelial cell density; ICL = implantable Collamer lens; IOP = intraocular pressure; OQAS = Optical Quality Analysis System; OSI = Objective Scatter Index; PRK = photorefractive keratectomy; UDVA = uncorrected distance visual acuity; WTW = white to white
The IOLMaster is manufactured by Carl Zeiss Meditec AG, and the Orbscan is manufactured by Bausch & Lomb.

angle, ICL with low vaulting of 8 to 12 μm, clear lens (**Figure 4**), and normal posterior segment. The patient was satisfied with her surgical result and postoperative follow-up. She was thankful we withheld immediate ICL explantation.

DISCUSSION

ICL implantation is now the best alternative for vision correction in patients with myopia who are not candidates for laser refractive surgery. However, in 4% of cases, complications may occur and may require ICL ex-

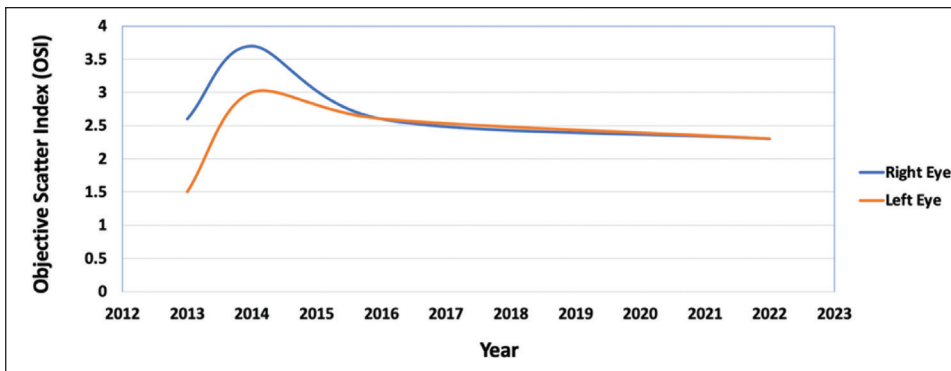


Figure 3. Graph showing double pass aberrometer results at different follow-up visits. Nine years of follow-up revealed almost stable Objective Scatter Index (OSI). One month postoperatively, bilateral transient increase in OSI score could be related to light diffraction by intraocular postoperative inflammation, which recovered completely. Further follow-up showed a return of the OSI score to its baseline. Therefore, no anatomical alteration responsible for light scatter and optical interference occurred during follow-up. OQAS = Optical Quality Analysis System

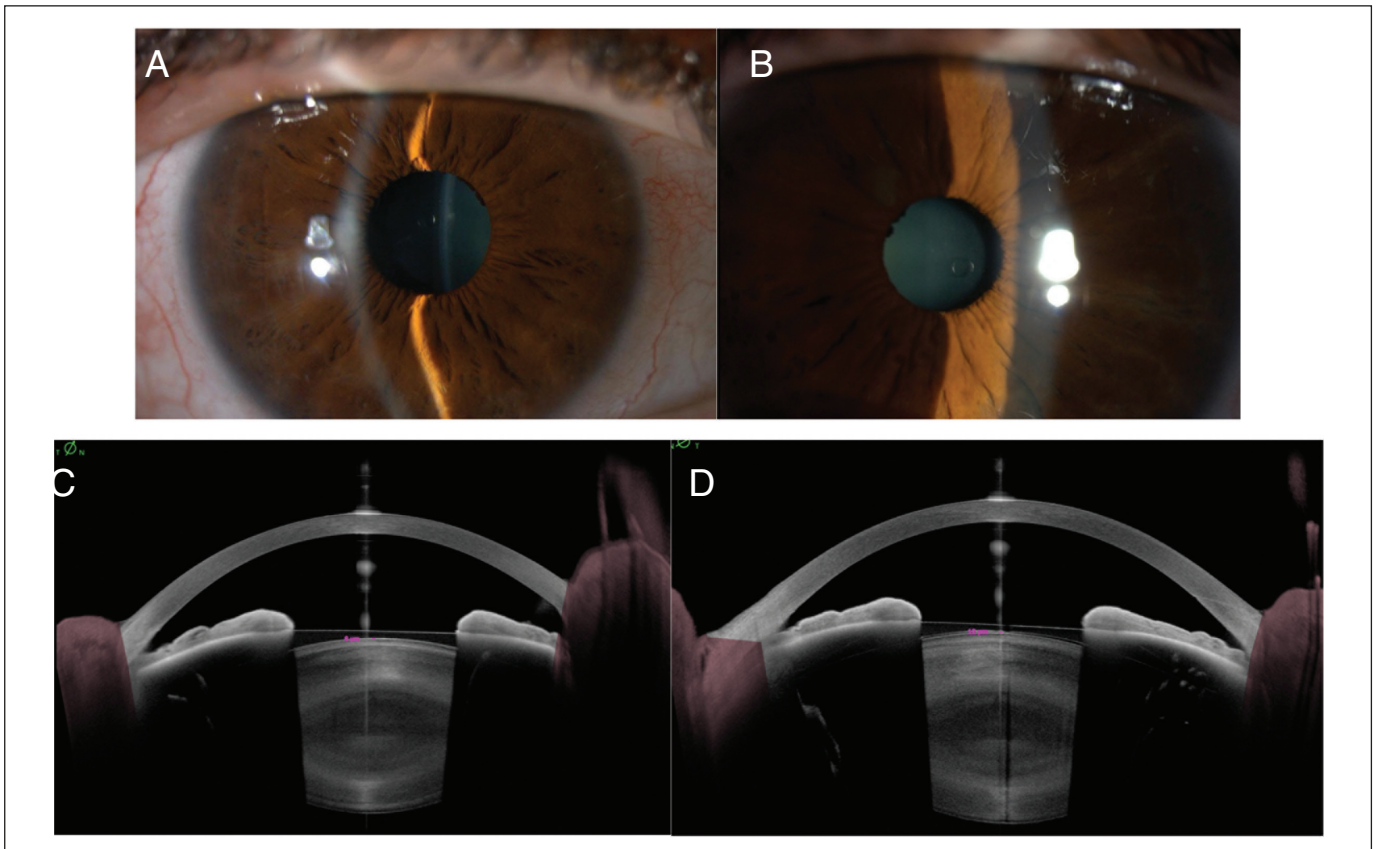


Figure 4. Nine years postoperatively (last follow-up visit). Slit-lamp examination of the (A) right and (B) left eyes showing very low implantable Collamer lens vaulting but no direct contact with lens and no subcapsular lens opacities. Anterior segment optical coherence tomography shows implantable Collamer lens vaulting of 8 and 12 μm in the (C) right and (D) left eye.

plantation. The average age at ICL explantation reported in the literature varied between 34.5 and 66.3 years. Low vaulting is the most common cause of ICL explantation or exchange.⁵ It is usually not advisable to observe these otherwise healthy young patients who are seeking elective surgery. Therefore, it has been recommended in the past to remove any ICL with vaulting below 150 μm to prevent subsequent cataract,³ with anterior subcapsular cataract being the prevalent type, occurring in 83.3% of cases at 3.4 ± 1.9 years after ICL implantation.⁶ A low lens vault halts aqueous flow over the anterior capsule

and impedes lens nutrition and metabolism, resulting in anterior subcapsular cataract development.

At the time of the surgery, our patient was 55 years old, but she had a clear lens, with an OSI score of 2.6 and 1.5 in the right and left eyes, respectively. In fact, the OSI score is known to be higher in individuals with myopia and should be interpreted with caution.⁷ Although lower order aberrations are corrected by the OQAS, higher refractive error is commonly associated with an increase in higher order aberrations and intraocular scattering, both altering the acquired retinal image. For this reason, we

consider OSI values of 1.5 and 2.6 with clinically clear lens likely attributable to high myopia. To keep her residual accommodative capacity and to protect her from higher risk of retinal detachment with clear lens extraction in comparison to ICL implantation, we opted for the latter to correct her myopia.

Although preoperative ICL sizing calculations were done according to the manufacturer's nomogram, postoperative ICL vaulting was low bilaterally (8 to 10 μm). A meta-analysis proved that unexpected vault results are not related to the sizing methodology and are dictated by the interaction of the pIOL with the anatomy and physiology of the posterior chamber.⁸ According to Trancón et al,⁹ 20% of patients who follow the V4c manufacturer's nomogram fall outside the accepted vault range (< 250 μm and/or > 1,000 μm). We acknowledge that borderline anterior chamber depth in our patient may have altered the preoperative vault estimation, but there is no trend direction relating anterior chamber depth to postoperative vault, and low vault has been reported in anterior chamber depth ranging from 2.47 to 3.35 mm.¹⁰ With the advent of the EVO Viva Implantable Collamer Lens, it is also expected to have older surgical candidates with subsequent narrowing of the anterior chamber depth¹¹ and preoperative recommendations should be revised.

Moreover, precise definitions for insufficient vault remain elusive. The lower limit of safe ICL vault reported in the literature varied between 50 and 250 μm .⁹ Gonvers et al¹² reported that although a vault of 90 μm or less was a risk factor for anterior subcapsular cataract, the majority of these eyes did not develop lens opacities. The ICL V4c has a 360- μm central hole that allows for the flow of aqueous humor centrally, thus reducing the risk of anterior capsular opacification. The U.S. Food and Drug Administration approved the safe range of the ICL as 250 to 1,000 μm based on the V4 model, prior to the release of the V4c model to which the Aquaport was added, and revision of these recommendations should be done in the future.

Finally, our patient maintained stable ICL vaulting and OSI scores over the course of 9 years. Low early postoperative ICL vault generally remains stable over time and does not worsen with progressive increase of lens size, as opposed to a higher early postoperative vault that is usually associated with progressive reduction.¹⁰ A low increase in OSI scores over the course of 9 years without repercussion on visual acuity may be related to clinically insignificant age-related lens changes, especially because our patient maintained a 20/20 visual acuity at her last follow-up visit, whereas anterior subcapsular cataract induced by ICL implantation is known to affect visual acuity.⁶

To our knowledge, this case represents the longest follow-up of an extreme low vault following ICL implantation. Low ICL vault is not a complication by itself, but it needs to be followed up. Withholding surgical intervention may be considered depending on the patient's age, characteristics, and compliance with close follow-up.

REFERENCES

1. Sanders DR, Doney K, Poco M; ICL in Treatment of Myopia Study Group. United States Food and Drug Administration clinical trial of the Implantable Collamer Lens (ICL) for moderate to high myopia: three-year follow-up. *Ophthalmology*. 2004;111(9):1683-1692. <https://doi.org/10.1016/j.ophtha.2004.03.026> PMID:15350323
2. Alfonso JF, Baamonde B, Fernández-Vega L, Fernandes P, González-Méijome JM, Montés-Micó R. Posterior chamber collagen copolymer phakic intraocular lenses to correct myopia: five-year follow-up. *J Cataract Refract Surg*. 2011;37(5):873-880. <https://doi.org/10.1016/j.jcrs.2010.11.040> PMID:21511154
3. Alhamzah A, Alharbi SS, Alfardan F, Aldebasi T, Almudhaiyan T. Indications for exchange or explantation of phakic implantable collamer lens with central port in patients with and without keratoconus. *Int J Ophthalmol*. 2021;14(11):1714-1720. <https://doi.org/10.18240/ijo.2021.11.10> PMID:34804861
4. AlSabaani NA, Behrens A, Jastanieh S, Al Malki S, Al Jindan M, Al Motowa S. Causes of phakic implantable collamer lens explantation/exchange at King Khaled Eye Specialist Hospital. *Middle East Afr J Ophthalmol*. 2016;23(4):293-295. <https://doi.org/10.4103/0974-9233.194076> PMID:27994391
5. Zeng QY, Xie XL, Chen Q. Prevention and management of collagen copolymer phakic intraocular lens exchange: causes and surgical techniques. *J Cataract Refract Surg*. 2015;41(3):576-584. <https://doi.org/10.1016/j.jcrs.2014.06.036> PMID:25804582
6. Kocová H, Vlková E, Michalcová L, Rybárová N, Motyka O. Incidence of cataract following implantation of a posterior-chamber phakic lens ICL (Implantable Collamer Lens): long-term results. *Cesk Slov Oftalmol*. 2017;73(3):87-93. PMID:29394074
7. Zhang XF, Qiao LY, Cai XG, et al. Analysis of related factors of optical quality in healthy Chinese adults: a community-based population study. *Chin Med J (Engl)*. 2020;133(19):2308-2314. <https://doi.org/10.1097/CM9.0000000000000994> PMID:32868501
8. Packer M. Meta-analysis and review: effectiveness, safety, and central port design of the intraocular collamer lens. *Clin Ophthalmol*. 2016;10:1059-1077. <https://doi.org/10.2147/OPHTH.S111620> PMID:27354760
9. Trancón AS, Manito SC, Sierra OT, Baptista AM, Serra PM. Determining vault size in implantable collamer lenses: preoperative anatomy and lens parameters. *J Cataract Refract Surg*. 2020;46(5):728-736. <https://doi.org/10.1097/j.jcrs.000000000000146> PMID:32358268
10. Kato S, Shimizu K, Igarashi A. Assessment of low-vault cases with an implantable collamer lens. *PLoS One*. 2020;15(11):e0241814. <https://doi.org/10.1371/journal.pone.0241814> PMID:33147267
11. Zeng Y, Liu X, Wang T, Zhong Y, Huang J, He M. Correlation between lens thickness and central anterior chamber depth. *Yan Ke Xue Bao*. 2012;27(3):124-126. <https://doi.org/10.3969/j.issn.1000-4432.2012.03.003> PMID:22993056
12. Gonvers M, Bornet C, Othenin-Girard P. Implantable contact lens for moderate to high myopia: relationship of vaulting to cataract formation. *J Cataract Refract Surg*. 2003;29(5):918-924. [https://doi.org/10.1016/S0886-3350\(03\)00065-8](https://doi.org/10.1016/S0886-3350(03)00065-8) PMID:12781276