



Collagen copolymer toric phakic intraocular lens for myopic astigmatism: One-year follow-up

José F. Alfonso, MD, PhD, Carlos Lisa, MD, PhD, Belén Alfonso-Bartolozzi, MD, Cari Pérez-Vives, MSc, Robert Montés-Micó, PhD

PURPOSE: To assess the predictability, stability, safety, and efficacy of a collagen copolymer toric phakic intraocular lens (pIOL) to correct moderate and high astigmatism.

SETTING: Fernández-Vega Ophthalmological Institute, Oviedo, Spain.

DESIGN: Case series.

METHODS: After implantation of the TV4b toric Implantable Collamer Lens pIOL, the uncorrected (UDVA) and corrected (CDVA) distance visual acuities, refraction, toric pIOL vault, and adverse effects were evaluated over 12 months.

RESULTS: The study enrolled 35 eyes of 20 patients with a mean sphere of -5.46 diopters (D) ± 4.17 (SD) and mean cylinder of -3.14 ± 1.19 D. At 12 months, the mean sphere was -0.04 ± 0.16 D, with 97% of eyes being within ± 0.50 D of the target ($r^2 = 0.99$), and the mean cylinder was -0.29 ± 0.42 D. For the astigmatism components, 80% of eyes were within ± 0.25 D of both J0 ($r^2 = 0.99$) and J45 ($r^2 = 0.99$). The mean decimal UDVA was 0.89 ± 0.16 and the mean decimal CDVA, 0.95 ± 0.12 . No eye lost lines of CDVA, and 43% of eyes gained 1 or more lines. The safety index was 1.08 at 12 months. More than 50% of eyes had a Snellen UDVA of 20/20. The efficacy index was 0.97 at 3 months and 1.01 at 12 months.

CONCLUSION: The visual and refractive outcomes were good and highly stable throughout the follow-up, indicating that this toric pIOL model is predictable, safe, and effective in correcting low and high levels of astigmatism.

Financial Disclosure: No author has a financial or proprietary interest in any material or method mentioned.

J Cataract Refract Surg 2014; 40:1155–1162 © 2014 ASCRS and ESCRS

Today, there are several options to correct refractive astigmatism besides spectacles and contact lenses. Options include surgical techniques. The most popular surgical method to correct refractive error is laser in situ keratomileusis, although the outcomes in correcting low or high astigmatism have not been successful or predictable.^{1,2} Another option is implantation of a toric phakic intraocular lens (pIOL).^{3–5}

The Visian Implantable Collamer Lens (Staar Surgical) is a posterior chamber pIOL approved by the U.S. Food and Drug Administration (FDA) to correct low to high myopia.^{6,7} Several studies^{8–14} have shown the pIOL to be stable, safe, predictable, and effective and to provide favorable visual quality results in the correction of moderate to severe astigmatism. In addition, toric pIOL implantation is reversible and leaves the central cornea

untouched, inducing fewer higher-order aberrations (HOAs) than other corneal refractive treatments.^{15–17}

The aim of the present study was to assess the clinical and refractive outcomes of the V4b toric model of the Implantable Collamer lens pIOL to correct low to high astigmatism over a 12-month follow-up. To our knowledge, several studies have assessed previous toric pIOL models; however, this is the first study to evaluate the V4b model.

PATIENTS AND METHODS

This prospective study comprised patients who had implantation of the V4b toric pIOL to correct low to high astigmatism at Fernández-Vega Ophthalmological Institute, Oviedo, Spain. In accordance with the Declaration of Helsinki, all patients provided written informed consent after

receiving a full explanation of the nature and possible consequences of the study. An institutional review board approved the study.

Inclusion criteria were a corrected distance visual acuity (CDVA) of 20/40 or better, stable refraction, and clear central cornea. The exclusion criteria included age younger than 22 years, anterior chamber depth less than 2.8 mm, endothelial cell density (ECD) less than 2000 cell/mm², cataract, a history of glaucoma or retinal detachment, macular degeneration or retinopathy, neuro-ophthalmic disease, and a history of ocular inflammation.

Before surgery, all patients had a complete ophthalmologic examination. The evaluation included manifest and cycloplegic refractions, keratometry, corneal topography, ECD, pachymetry, slitlamp microscopy, Goldmann applanation tonometry, and binocular indirect ophthalmoscopy through a dilated pupil.

Phakic Intraocular Lens Size and Power Calculation

The V4b is a plate-haptic single-piece pIOL designed to be implanted in the posterior chamber with support on the ciliary sulcus. It is partly made of a collagen copolymer (Collamer), which is a flexible, hydrophilic, and biocompatible material. The IOL has a central convex-concave optic zone and a cylinder component to correct astigmatism. To minimize rotation, the surgeon cannot rotate the pIOL more than 10 degrees from the horizontal meridian. The previous toric pIOL model (model V4) was stored in sodium chloride; in contrast, the model used in this study is stored in a balanced salt solution, making the lens power closer to the spectacle refraction. The toric pIOL has a guide showing the amount and direction of rotation from the horizontal axis required to align the pIOL cylinder axis to the required cylinder correction. With the exception of the requirement to mark the horizontal axis and rotate the toric pIOL in some cases, the surgical technique is the same as for the spherical model of the pIOL. To control for potential cyclotorsion with the patient supine, the surgeon marked the zero horizontal axis at the slitlamp with the patient upright. The surgeon also used a Mendez ring (Moria) to measure the required rotation from horizontal during surgery. The IOL power calculation was performed using software provided by the manufacturer. The targeted refraction was emmetropia in all cases.

Submitted: September 5, 2013.

Accepted: November 11, 2013.

From the Fernández-Vega Ophthalmological Institute (Alfonso, Lisa), and the Surgery Department (Alfonso), School of Medicine, University of Oviedo, Oviedo, the Department of Ophthalmology (Alfonso-Bartolozzi), Clínica Universidad de Navarra, Pamplona, and the Optics Department (Pérez-Vives, Montés-Micó), Faculty of Physics, University of Valencia, Valencia, Spain.

Supported in part by the VALi+D research scholarship Generalitat Valenciana, Spain (Ms. Pérez-Vives).

Corresponding author: José F. Alfonso, MD, PhD, Instituto Oftalmológico Fernández-Vega, Avenida Doctores Fernández-Vega 114 33012 Oviedo, Spain. E-mail: j.alfonso@fernandez-vega.com.

Surgical Technique

The same experienced surgeon (J.F.A) performed all surgeries through a 3.2 mm clear corneal tunnel incision in the horizontal meridian using peribulbar anesthesia. Intraoperative iridectomy was performed 1 week before surgery. Thirty minutes before surgery, tropicamide and phenylephrine eyedrops were instilled. Five minutes before surgery, povidone-iodine 5.0% (Betadine) was applied. The anterior chamber was filled with sodium hyaluronate 1.0% (Provisc), which was completely removed at the end of surgery. Tobramycin and dexamethasone 0.1% eyedrops were used 4 times a day for 10 days, after which diclofenac sodium eyedrops were started 4 times a day for 2 weeks. In cases of bilateral implantation, the second eye was operated on within the first week of surgery on the fellow eye.

Follow-up

Periodic assessments of patients were performed after surgery at 3, 6, and 12 months. The examinations included uncorrected distance visual acuity (UDVA), CDVA, refractive status, slitlamp evaluation, tonometry, and objective vault assessment through optical coherence tomography (Visante, Carl Zeiss Meditec AG). For averaging, visual acuities were converted to logMAR values; then, the means and standard deviations were back-calculated to Snellen acuity. The vault between the crystalline lens and the pIOL was measured perpendicular to the lens apex or at the narrowest space between the 2.

Manifest refractions in conventional script notation (S [sphere], C [cylinder], α [axis]) were converted to power vector coordinates and overall blurring strength by the following formulas¹⁸: $M = S + C/2$; $J0 = (-C/2) \times \cos(2\alpha)$; $J45 = (-C/2) \times \sin(2\alpha)$; $B = (M^2 + J0^2 + J45^2)^{1/2}$. In these equations, M is equal to the spherical equivalent (SE) of the given refractive error, J0 and J45 are the 2 Jackson crossed-cylinders equivalent to the conventional cylinder, and B is the length of a vector that represents overall blurring strength.

Outcome Measures

Assessment of outcomes was based on preoperative versus postoperative CDVA and UDVA values (efficacy and safety) and the achieved versus the expected refractive outcomes postoperatively (predictability). The efficacy index (ratio of postoperative UDVA to preoperative CDVA) and the safety index (ratio of postoperative to preoperative CDVA) were also calculated.

Statistical Analysis

Data analysis was performed using SPSS software (version 20.0, SPSS, Inc.). Normality of the data was checked by the Kolmogorov-Smirnov test. Comparison of means was by the nonparametric Wilcoxon signed-rank test. The Hotelling T2 test of multivariate analysis was used to assess statistically significant differences in refractive values and visual acuity outcomes. Differences were considered statistically significant when the *P* value was less than 0.05.

RESULTS

The present study enrolled 35 eyes of 20 patients, of which 6 (30%) were men and 14 women (70%).

Table 1. Preoperative patient demographics and pIOL characteristics.

Parameter	Mean ± SD	Range
Patients		
Age (y)	28.26 ± 3.65	22, 38
Refraction (D)		
Sphere	-5.46 ± 4.17	-12.00, 3.00
Cylinder	-3.14 ± 1.19	-6.00, -1.50
Keratometry (D)		
Flat	42.31 ± 1.55	39.50, 45.75
Steep	45.17 ± 1.77	42.5, 48.5
ECD (cells/mm ²)	2755.09 ± 405.82	2140, 4100
IOP (mm Hg)	12.66 ± 2.14	8.00, 18.00
Pupil size (mm)		
Photopic	4.97 ± 0.65	4.00, 6.00
Scotopic	7.00 ± 0.73	6.00, 8.00
Phakic IOL		
Size (mm)	13.15 ± 0.30	12.6, 13.7
Sphere (D)	-9.54 ± 4.09	-15.5, -1.0
Cylinder (D)	3.27 ± 1.38	1, 6

ECD = endothelial cell density; IOL = intraocular lens; IOP = intraocular pressure

Table 1 shows the preoperative patients' demographics and the pIOL characteristics.

Predictability

Figure 1 shows the distribution of the refractive cylinder preoperatively and 12 months postoperatively. The mean manifest refractive cylinder decreased from -3.14 ± 1.19 diopters (D) preoperatively to -0.29 ± 0.42 D at 12 months postoperatively. At 12 months, all eyes had 1.00 D or less of refractive cylinder, 25 eyes (71.4%) had 0.50 D or less, and 23 eyes (65.7%) had 0.25 D or less.

Figure 2 shows the attempted refraction versus achieved refraction plots for M, J0, and J45 values 12 months postoperatively. At 3 months, 30 eyes (85.7%), 32 eyes (91.4%), and 33 eyes (94.3%) were within ± 0.50 D for M, J0, and J45, respectively. At 12 months, 34 eyes (97.1%) were within ± 0.50 D of the M component and all eyes were within ± 1.00 D ($r^2 = 0.99$) of the desired SE refraction. For the astigmatism components, 28 eyes (80.0%) were within ± 0.25 D and all eyes were within ± 0.50 D for J0 ($r^2 = 0.99$) and J45 ($r^2 = 0.99$), respectively.

Stability

Table 2 shows the distribution of the preoperative and postoperative manifest refraction data after vector conversion. The power vectors decreased after surgery and remained stable over time. There were no statistically significant differences in the M, J0, and J45

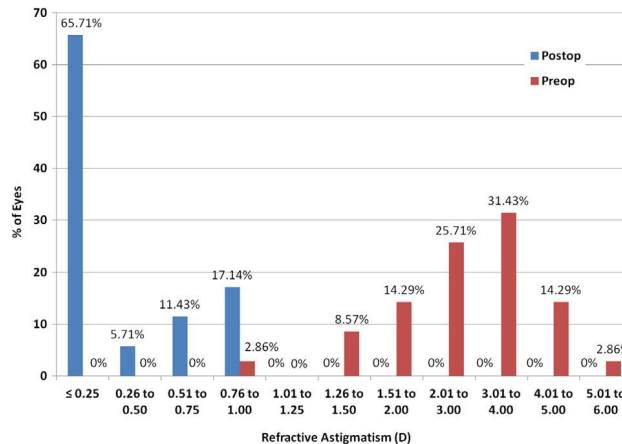


Figure 1. Preoperative versus postoperative manifest refractive astigmatism in all 35 eyes 12 months postoperatively.

refractive components between each pair of visits during the 12-month follow-up ($P > .005$, Wilcoxon signed-rank test) except for the J45 refractive component between the 3-month and 6-month follow-up visits ($P = 0.028$, Wilcoxon signed-rank test); the outcomes were better at 6 months. Figure 3 shows the improvement in the SE refractive error and stability of refraction over time. Figure 4 shows the astigmatic components of the power vector represented by the 2-dimensional vector (J0, J45). Twelve months after surgery, the distribution of points is tighter around zero than the preoperative data. The origin in this graph (0,0) represents an eye free of astigmatism. The multivariate Hotelling T^2 test confirmed that the

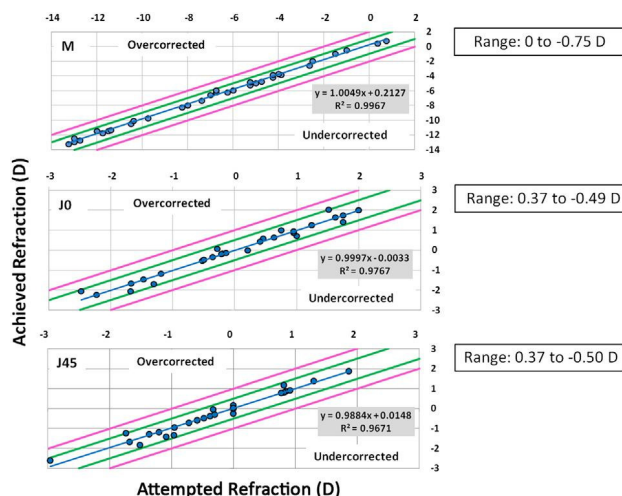


Figure 2. Achieved correction versus attempted correction (predictability) of SE (M) and the astigmatic components (J0 and J45) 12 months postoperatively in all 35 eyes. The coefficients of determination (r^2) were 0.99, 0.96, and 0.96 for M, J0, and J45, respectively (see Table 2 for mean values) (J0 = Jackson cross-cylinder, axes 180 degrees and 90 degrees; J45 = Jackson cross-cylinder, axes at 45 degrees and 135 degrees; M = spherical equivalent).

Table 2. Mean values of vectorial decomposition components before and after pIOL implantation.

Component	Mean ± SD			
	Preoperative	Postoperative		
		3 Months	6 Months	12 Months
M	-7.03 ± 4.07	-0.22 ± 0.34	-0.21 ± 0.39	-0.18 ± 0.24
J0	0.16 ± 1.32	0.05 ± 0.27	0.04 ± 0.27	0.00 ± 0.18
J45	-0.26 ± 1.03	0.04 ± 0.24	0.003 ± 0.23	-0.01 ± 0.17
B	7.42 ± 3.68	0.39 ± 0.39	0.40 ± 0.40	0.24 ± 0.31

B = blur component of vectorial decomposition of refraction; J0 = Jackson cross-cylinder, axes 180 degrees and 90 degrees; J45 = Jackson cross-cylinder, axes at 45 degrees and 135 degrees; M = spherical equivalent

mean power vector after surgery was not significantly different from a vector of zero length ($P = .705$).

up, the CDVA was 20/25 or better in 31 eyes (88.6%) and 20/32 or better in all eyes.

Safety

Figure 5 shows the safety results 12 months postoperatively. By 3 months, no eye had lost lines of CDVA, 20 eyes had no change from preoperatively, 8 eyes had gained 2 lines, and 1 eye had gained more than 2 lines. The safety index at 3 months was 1.07. By 6 months, no eye had lost any lines of CDVA, 19 eyes had no change from preoperatively, 9 eyes had gained 1 line, 6 eyes had gained 2 lines, and 1 eye had gained more than 2 lines. The safety index at 6 months was 1.08. By 12 months, no eye had lost any lines of CDVA, 20 eyes had no change from preoperatively, 8 eyes had gained 1 line, 6 eyes had gained 2 lines, and 1 eye had gained more than 2 lines. The safety index at 12 months was 1.08.

Figure 6 shows the cumulative Snellen CDVA preoperatively and 12 months postoperatively. There was an improvement in the proportion of eyes with a CDVA of 20/20 or better from preoperatively to 12 months postoperatively. By the 12-month follow-

Efficacy

Preoperatively, the mean Snellen decimal UDVA was 0.03 ± 0.08 (range 0.0 to 0.4) and the mean CDVA was 0.88 ± 0.15 (range 0.5 to 1.0). Postoperatively, the mean Snellen decimal UDVA was 0.86 ± 0.17 (range 0.4 to 0.1) at 3 months, 0.87 ± 0.16 (range 0.4 to 1.0) at 6 months, and 0.89 ± 0.16 (range 0.4 to 1.0) at 12 months. The mean CDVA was 0.94 ± 0.11 (range 0.6 to 1.0) at 3 months, 0.95 ± 0.12 (range 0.6 to 1.0) at 6 months, and 0.95 ± 0.12 (range 0.6 to 1.0) at 12 months.

Figure 7 shows the changes in the UDVA and CDVA and the efficacy index. There was no statistically significant difference between the UDVA 12 months postoperatively and the CDVA preoperatively ($P > .05$, Wilcoxon signed-rank test). The overall

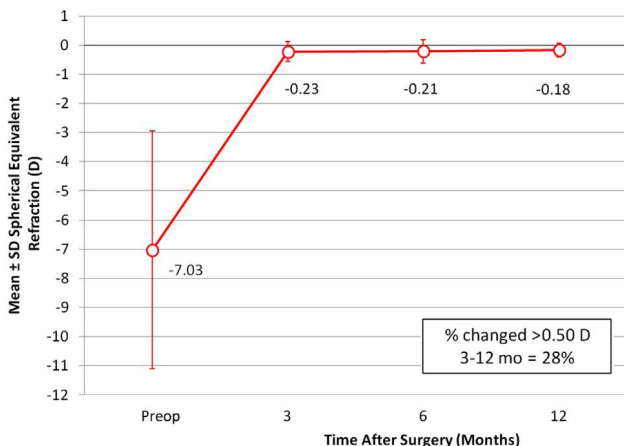


Figure 3. Time course of the SE (M) (stability) in all 35 eyes.

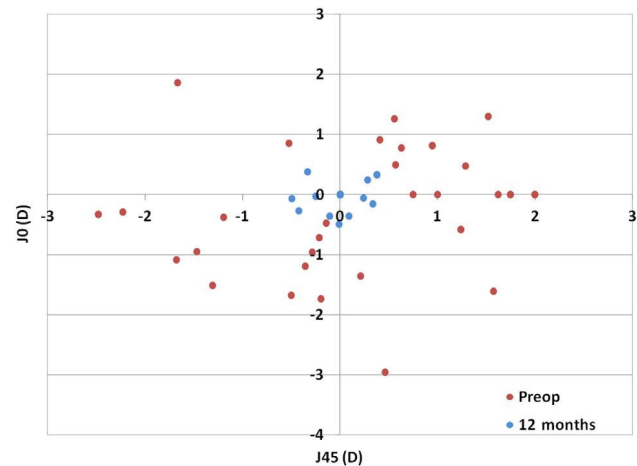


Figure 4. Preoperative and 12-month postoperative astigmatic vectors. The more central location of postoperative data around 0 represents a reduction in astigmatism after toric pIOL implantation (J0 = Jackson cross-cylinder, axes at 180 degrees and 90 degrees; J45 = Jackson cross-cylinder, axes at 45 degrees and 135 degrees).

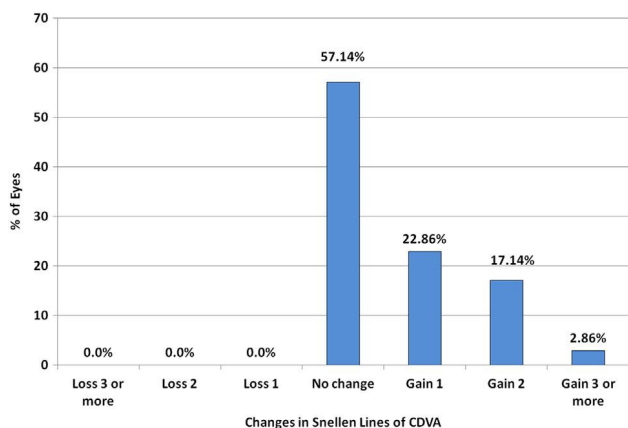


Figure 5. Postoperative changes in CDVA in all 35 eyes 12 months postoperatively (CDVA = corrected distance visual acuity).

efficacy index improved from 3 months to 12 months postoperatively. The proportion of eyes with a UDVA of 20/20 or better 12 months postoperatively (18 eyes [51.42%]) was higher than the proportion with a preoperative CDVA of 20/20 or better (15 eyes, 42.85%). The proportion of eyes with 20/40 or better postoperative UDVA and 20/40 or better preoperative CDVA was equal (28 eyes [80.0%]). The 12-month postoperative UDVA was the same as the preoperative CDVA in 15 eyes (42.85%), was better than the preoperative CDVA in 12 eyes (34.28%), and was worse than the preoperative CDVA in 8 eyes (22.85%).

Adverse Effects

There were no intraoperative complications, and no pIOL was repositioned or required explantation. There were no cases of pIOL decentration. At 12 months, the mean ECD was 2634 ± 281.8 cells/mm² (range 2292 to

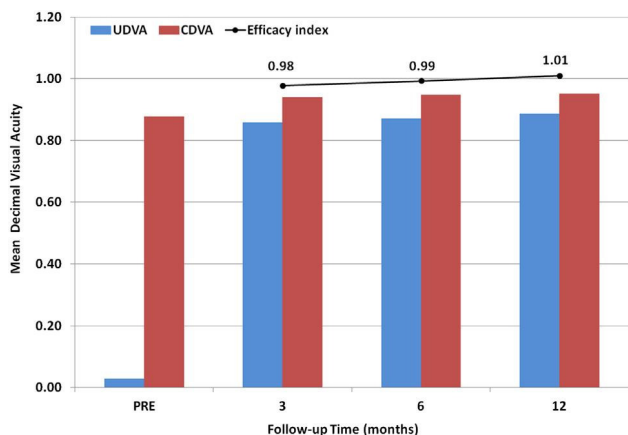


Figure 7. Postoperative UDVA, CDVA, and efficacy in all 35 eyes 12 months postoperatively (CDVA = corrected distance visual acuity; UDVA = uncorrected distance visual acuity).

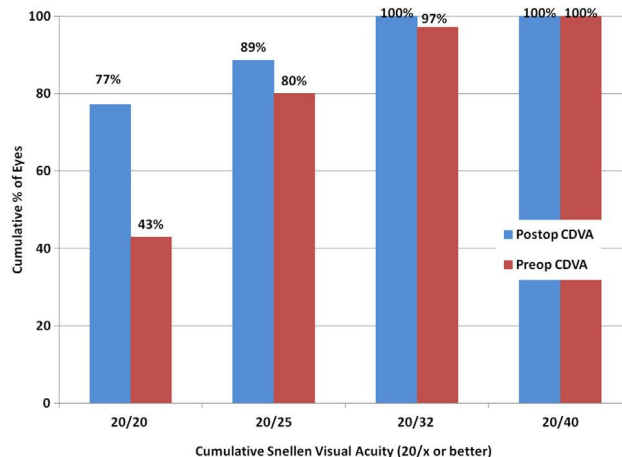


Figure 6. Preoperative CDVA versus 12-month postoperative CDVA in all 35 eyes (CDVA = corrected distance visual acuity).

3384 cells/mm²). No eye had increased intraocular pressure (IOP), pupillary block, or anterior subcapsular cataract. At the 3-, 6-, and 12-month follow-ups, the mean pIOL vault was 567.7 ± 128.3 μ m (range 350 to 860 μ m), 541.5 ± 179.5 μ m (range 200 to 1020 μ m), and 594.3 ± 155.9 μ m (range 200 to 810 μ m), respectively. Throughout the follow-up, the mean differences in vault were small and not statistically significant ($P > .05$, Wilcoxon signed-rank test).

DISCUSSION

In the present study, we analyzed the visual and refractive outcomes after implantation of a new toric pIOL model in 35 eyes of 20 patients. The aim was to determine whether this new model is safe, effective, and predictable in correcting myopic and hyperopic astigmatism through 1 year of follow-up.

The visual outcomes were satisfactory in relation to the safety index and efficacy index. The safety index was 1.08 12 months postoperatively, by which time no eye had lost lines of CDVA and 43% of eyes had gained 1 or more lines of CDVA. The percentage of eyes with a CDVA of 20/20 increased from 43% preoperatively to more than 75% postoperatively. The efficacy index at 12 months was 1.01. There was an improvement in UDVA 12 months postoperatively compared with the CDVA preoperatively; more than 50% of eyes had a UDVA of 20/20 or better at 12 months, and 43% of eyes had a CDVA of 20/20 preoperatively. Most eyes had a UDVA of 20/25 or better.

The predictability and stability outcomes were also good; 65% of eyes had -0.25 D of refractive cylinder or less at 12 months. There was a high correlation between the attempted refraction and achieved refraction for the sphere and cylinder components; more than 95% of eyes were within ± 0.50 D of the SE

refraction of the M component and all eyes were within ± 0.50 D of the desired refraction of the J0 and J45 components at 12 months. The M component was stable through the follow-up, changing less than 0.10 D from 3 months to 12 months. Vectorial analysis of astigmatism showed that the postoperative cylindrical components of refraction were not significantly different from zero.

Several studies have analyzed previous models of the Implantable Collamer Lens pIOL. In an FDA clinical study, Sanders et al.⁸ assessed the previous toric pIOL model in 210 eyes of 124 patients with a 12-month follow-up. In that study, more than 75% of eyes gained 1 or more lines of CDVA and 3 eyes lost 2 or more lines of CDVA after 12 months. The proportion of eyes with a CDVA and UDVA of 20/20 or better was 96.8% and 83.1%, respectively. At 12 months, more than 75% of eyes had a UDVA that was the same as or better than the preoperative CDVA. Spherical and astigmatism errors were reduced in all cases postoperatively. The mean refractive cylinder decreased from 1.93 D preoperatively to 0.50 D postoperatively, a 73.6% reduction in astigmatism. The mean manifest refraction SE (MRSE) improved from -9.36 D preoperatively to 0.05 D postoperatively; 76.9% of eyes were within ± 0.50 D of the predicted MRSE and 97.3% were within ± 1.00 D.

In a study by Park et al.,¹⁰ no patient lost CDVA at last follow-up after toric pIOL implantation. At 7.6 months, the CDVA and UDVA were 20/20 or better in 86.7% of eyes and 66.7% of eyes, respectively. The mean MRSE improved from -10.63 D preoperatively to 0.04 D 7.6 months postoperatively; 70% of eyes were within ± 0.50 D of emmetropia after surgery. The mean manifest refraction cylinder decreased from 2.43 D preoperatively to 0.73 D postoperatively. In a study by Bhikoo et al.,¹¹ 66% of 77 eyes had a UDVA of 20/20 or better, 78% gained 1 line of CDVA, and 1% lost 1 line of CDVA. After toric pIOL implantation, the mean refractive cylinder dropped from 2.38 D to 0.44 D.

Alfonso et al.¹² evaluated the V4 Implantable Collamer Lens toric pIOL for myopic astigmatism over a 1-year follow-up. They found that implantation of a toric pIOL was highly predictable, stable, and safe up to 1 year postoperatively. Most eyes maintained or had improved CDVA, and the safety index was higher than 1.00 at all follow-up visits. By 12 months, 1 eye had lost 2 lines of CDVA, 20 eyes had no change from preoperatively, and 31 eyes had gained 1 or more lines. The proportion of eyes with a CDVA of 20/20 or better increased from 20% at baseline to 61.8% at 12 months. In addition, the number of eyes with a UDVA of 20/20 or better at 12 months (33 eyes [60%]) was higher than the number of eyes with a

preoperative CDVA of 20/20 or better (11 eyes [20%]). The efficacy index at 12 months was 1.08. All eyes were within ± 1.00 D of the attempted SE, and more than 90% of eyes were within ± 0.50 D for all components evaluated (M, J0, and J45). The M component was stable throughout the follow-up, changing by approximately 0.50 D from 1 to 12 months.

In another study, Alfonso et al.¹³ evaluated the V4 Implantable Collamer Lens toric pIOL to correct high myopic astigmatism. The mean refractive cylinder decreased from -4.85 D preoperatively to -0.55 D postoperatively, with 93.3% of eyes having less than 1.00 D of cylinder. The mean SE was -0.31 D, with more than 70% of eyes within ± 0.50 of the target. For the astigmatic components, 93.3% of eyes were within ± 1.00 D of J0 and all eyes were within ± 1.00 D of J45. By 12 months, no eye had lost more than 2 lines of CDVA, more than 70% of eyes remained unchanged, and 30% of eyes had gained 1 or more lines of CDVA. The safety index at 12 months was 1.07. The proportion of eyes with a CDVA of 20/20 or better increased from 13% preoperatively to 27% 12 months postoperatively. All eyes had a CDVA of 20/32 or better and 80% of eyes had a UDVA of 20/32 or better 12 months postoperatively.

Kamiya et al.¹⁴ analyzed 1-year outcomes of V4 Implantable Collamer Lens toric pIOL implantation for moderate to high myopic astigmatism. In that study, 5% of eyes had lost 1 line of CDVA and 52% of eyes had gained more than 1 line of CDVA by 12 months postoperatively. The mean CDVA and UDVA at 12 months were better than 20/20. The safety index was 1.17 and the efficacy index, 1.00. By 12 months, 91% of eyes and 100% of eyes were within ± 0.50 D and ± 1.00 D, respectively, of the attempted correction.

All these studies analyzed the previous V4 model to correct low and high myopic astigmatism and reported good safety, efficacy, predictability, and stability outcomes for at least 1 year postoperatively. Our results with the newer V4b model were comparable or better than those in these previous studies.

Previous FDA studies of the Implantable Collamer Lens pIOL to correct moderate to high levels of myopia^{6,7} showed good predictability, stability, safety, and efficacy. At the 3-year follow-up, 59.3% of 526 eyes had a CDVA of 20/20 or better and 94.7% had a UDVA of 20/40 or better; 67.5% of patients were within ± 0.50 D of the predicted refraction and 88.2% were within ± 1.00 D.⁷ The mean improvement in CDVA was between 0.5 and 0.6 lines; 3 eyes (0.8%) lost 2 or more lines of CDVA, and 40 eyes (10.8%) gained 2 or more lines of CDVA. These FDA outcomes agree with our results.

Some postoperative complications after implantation of these toric pIOLs have been described.¹⁹ The most common include endothelial cell loss²⁰; pupillary block²¹; increased IOP²²; anterior subcapsular cataract,²³ and insufficient vault,^{24–26} which could cause an anterior subcapsular cataract; surgical trauma; or continuous pIOL–crystalline lens contact. In the present study, no eye had increased IOP or developed a chronic increase in IOP or a subcapsular cataract during the follow-up. In addition, we found no statistically significant differences in vault throughout 12 months.

In conclusion, the implantation of the new V4b model of the Implantable Collamer Lens toric pIOL gave good outcomes, improving UDVA and CDVA immediately after surgery and being highly consistent throughout the 12-month follow-up. In addition, the refractive outcomes were good. The toric pIOL showed high predictability and stability over 12 months. Our predictability, stability, safety, and efficacy results agree with those in studies of the previous toric pIOL. Thus, the V4b Implantable Collamer Lens toric pIOL is a good alternative to correct myopic and hyperopic astigmatism. Future studies with larger samples and a longer follow-up are needed to fully examine the outcomes of this toric pIOL model.

WHAT WAS KNOWN

- Previous toric pIOL models were shown to be effective and safe in correcting low and high levels of astigmatism.

WHAT THIS PAPER ADDS

- This first study analyzing the outcomes after implantation of the new model of the toric pIOL confirmed it to be an effective and safe procedure to correct low and high levels of astigmatism.

REFERENCES

1. Frings A, Katz T, Richard G, Druchkiv V, Linke SJ. Efficacy and predictability of laser in situ keratomileusis for low astigmatism of 0.75 diopter or less. *J Cataract Refract Surg* 2013; 39:366–377
2. Ivarsen A, Næser K, Hjortdal J. Laser in situ keratomileusis for high astigmatism in myopic and hyperopic eyes. *J Cataract Refract Surg* 2013; 39:74–80
3. Dick HB, Alió J, Bianchetti M, Budo C, Christiaans BJ, El-Danasoury MA, Güell JL, Krumeich J, Landesz M, Loureiro F, Luyten GPM, Marinho A, Rahhal MS, Schwenn O, Spirig R, Thomann U, Venter J. Toric phakic intraocular lens; European multicenter study. *Ophthalmology* 2003; 110:150–162
4. Tehrani M, Dick HB. Iris-fixated toric phakic intraocular lens: three-year follow-up. *J Cataract Refract Surg* 2006; 32:1301–1306
5. Güell JL, Morral M, Gris O, Gaytan J, Sisquella M, Manero F. Five-year follow-up of 399 phakic Artisan-Verisyse implantation for myopia, hyperopia, and/or astigmatism. *Ophthalmology* 2008; 115:1002–1012
6. The Implantable Contact Lens in Treatment of Myopia (ITM) Study Group. U.S. Food and Drug Administration clinical trial of the Implantable Contact Lens for moderate to high myopia. *Ophthalmology* 2003; 110:255–266. Available at: <http://old.iloveeye.com/pds/FDA.pdf>. Accessed March 21, 2014
7. ICL in Treatment of Myopia (ITM) Study Group. United States Food and Drug Administration clinical trial of the Implantable Collamer Lens (ICL) for moderate to high myopia; three-year follow-up. *Ophthalmology* 2004; 111:1683–1692
8. Sanders DR, Schneider D, Martin R, Brown D, Dulaney D, Vukich J, Slade S, Schallhorn S. Toric Implantable Oollamer Lens for moderate to high myopic astigmatism. *Ophthalmology* 2007; 114:54–61
9. Hashem AN, El Danasoury AM, Anwar HM. Axis alignment and rotational stability after implantation of the toric implantable collamer lens for myopic astigmatism. *J Refract Surg* 2009; 25:S939–S943
10. Park SC, Kwun YK, Chung E-S, Ahn K, Chung T-Y. Postoperative astigmatism and axis stability after implantation of the STAAR Toric Implantable Collamer Lens. *J Refract Surg* 2009; 25:403–409
11. Bhikoo R, Rayner S, Gray T. Toric implantable collamer lens for patients with moderate to severe myopic astigmatism: 12-month follow-up. *Clin Exp Ophthalmol* 2010; 38:467–474
12. Alfonso JF, Fernández-Vega L, Fernandes P, González-Méijome JM, Montés-Micó R. Collagen copolymer toric posterior chamber phakic intraocular lens for myopic astigmatism; one-year follow-up. *J Cataract Refract Surg* 2010; 36:568–576
13. Alfonso JF, Baamonde B, Madrid-Costa D, Fernandes P, Jorge J, Montés-Micó R. Collagen copolymer toric posterior chamber phakic intraocular lenses to correct high myopic astigmatism. *J Cataract Refract Surg* 2010; 36:1349–1357
14. Kamiya K, Shimizu K, Aizawa D, Igarashi A, Komatsu M, Nakamura A. One-year follow-up of posterior chamber toric phakic intraocular lens implantation for moderate to high myopic astigmatism. *Ophthalmology* 2010; 117:2287–2294
15. Sanders D, Vukich JA. Comparison of implantable collamer lens (ICL) and laser-assisted in situ keratomileusis (LASIK) for low myopia. *Cornea* 2006; 25:1139–1146
16. Shin JY, Ahn H, Seo KY, Kim EK, Kim T-i. Comparison of higher order aberrations after Implantable Collamer Lens implantation and wavefront-guided LASEK in high myopia. *J Refract Surg* 2012; 28:106–111
17. Pérez-Vives C, Domínguez-Vicent A, García-Lázaro S, Ferrer-Blasco T, Montés-Micó R. Optical and visual quality comparison of implantable Collamer lens and laser in situ keratomileusis for myopia using an adaptive optics visual simulator. *Eur J Ophthalmol* 2013; 23:39–46
18. Thibos LN, Horner D. Power vector analysis of the optical outcome of refractive surgery. *J Cataract Refract Surg* 2001; 27:80–85
19. Fernandes P, González-Méijome JM, Madrid-Costa D, Ferrer-Blasco T, Jorge J, Montés-Micó R. Implantable Collamer posterior chamber intraocular lenses: a review of potential complications. *J Refract Surg* 2011; 27:765–776
20. Edelhauser HF, Sanders DR, Azar R, Lamielle H. ICL in Treatment of Myopia Study Group. Corneal endothelial assessment after ICL implantation. *J Cataract Refract Surg* 2004; 30:576–583

21. Smallman DS, Probst L, Rafuse PE. Pupillary block glaucoma secondary to posterior chamber phakic intraocular lens implantation for high myopia. *J Cataract Refract Surg* 2004; 30:905–907
22. Sánchez-Galeana CA, Zadok D, Montes M, Cortés MA, Chayet AS. Refractory intraocular pressure increase after phakic posterior chamber intraocular lens implantation. *Am J Ophthalmol* 2002; 134:121–123
23. Sánchez-Galeana CA, Smith RJ, Sanders DR, Rodríguez FX, Litwak S, Montes M, Chayet AS. Lens opacities after posterior chamber phakic intraocular lens implantation. *Ophthalmology* 2003; 110:781–785
24. Alfonso JF, Baamonde B, Fernández-Vega L, Fernandes P, González-Méijome JM, Montés-Micó R. Posterior chamber collagen copolymer phakic intraocular lenses to correct myopia: five-year follow-up. *J Cataract Refract Surg* 2011; 37:873–880
25. Alfonso JF, Lisa C, Abdelhamid A, Fernandes P, Jorge J, Montés-Micó R. Three-year follow-up of subjective vault following myopic implantable collamer lens implantation. *Graefes Arch Clin Exp Ophthalmol* 2010; 248:1827–1835
26. Alfonso JF, Fernández-Vega L, Lisa C, Fernandes P, Jorge J, Montés-Micó R. Central vault after phakic intraocular lens implantation: correlation with anterior chamber depth, white-to-white distance, spherical equivalent, and patient age. *J Cataract Refract Surg* 2012; 38:46–53



First author:

José F. Alfonso, MD, PhD

*Fernández-Vega Ophthalmological
Institute, Oviedo, Spain*